

## COMPREHENSIVE RECONSTRUCTIVE SURGERY FOR OBSTRUCTIVE SLEEP APNEA

Wayne B. Colin, DMD, MD

*Obstructive sleep apnea (OSA) is commonly treated by continuous positive airway pressure (CPAP). Patients can be intolerant, noncompliant, or avoidant of CPAP therapy but incur increased risk of cardiopulmonary disease, stroke, and shortened life span without treatment. Comprehensive hard and soft tissue surgical therapy directed at the nasal, retro-palatal, and retro-lingual airway has been shown to optimize surgical outcomes compared with isolated soft tissue procedures. Outcome information from postoperative sleep studies shows that staged surgical procedures of hard and soft tissues are comparable to CPAP studies. While CPAP is the "gold standard" therapy for obstructive sleep apnea, combined soft tissue and maxillofacial surgical techniques can provide a treatment alternative for patients that are unable or unwilling to use CPAP treatment.*

**O**bststructive sleep apnea (OSA) is characterized by dynamic occlusion of the upper airway at one or more sites during sleep.<sup>1</sup> The obstruction to the airway is commonly treated by forcing room air into the nose or mouth through the use of a continuous positive airway pressure (CPAP) machine and mask.<sup>2</sup> CPAP treatment

can be tolerated by many patients,<sup>3,4</sup> but long-term acceptance and compliance is difficult to predict.<sup>5</sup> Other noninvasive treatments include weight loss, change in sleep position or jaw advancement appliances.<sup>6</sup> Moreover, it is common knowledge<sup>7</sup> that alcohol, narcotics, tranquilizers, sedatives, or antihistamines can adversely impact OSA.

Tobacco use may be an independent risk factor for OSA<sup>8</sup> and is condemned for its adverse effects on lung function and strong association with carcinoma of the upper aerodigestive tract. Gastroesophageal reflux has also been implicated in the etiology of OSA<sup>9,10</sup> and its treatment has been shown to reduce OSA severity.

Although the standard nonsurgical treatment of OSA is CPAP, not every patient is able, interested, or motivated to use CPAP as prescribed. In addition, the definition of adequate CPAP therapy (hours per night and number of nights per week) remains controversial.<sup>11</sup> Since untreated OSA is known to have profound medical risks<sup>12</sup> including hypertension,<sup>13-15</sup> ischemic heart disease,<sup>16-17</sup> cerebrovascular disease,<sup>18-19</sup> neuro-cognitive impairment,<sup>20-21</sup> premature mortality<sup>22-23</sup> and magnified risk of motor vehicle accidents,<sup>24</sup> discontinuance of CPAP therapy cannot be condoned. Indeed CPAP is not a cure for OSA, but a support measure that must be used every time one sleeps. On the other hand, surgery can predictably treat and even "cure" the problem with a durable result without nightly CPAP therapy, as will be outlined below.

## Case 1

JB, a 44-year-old nurse, was diagnosed with moderate obstructive sleep apnea with respiratory disturbance index (RDI) (see Table of Abbreviations, page 160) of 22. She was intolerant of CPAP due to claustrophobia and inadvertent nighttime removal of the CPAP mask. Her physical findings were unremarkable. She underwent inferior turbinate reduction, palatoplasty, and genioglossus advancement. Seen three months after surgery, she reported no

*The author and illustrator is a Lexington otolaryngologist and may be contacted at: Lexington Clinic, Otolaryngology Head and Neck Surgery, 1221 S Broadway, Lexington, KY 40504. For more information, go to Dr. Colin's Web site, [www.osasurgery.com](http://www.osasurgery.com).*

snoring, resolution of her day-time sleepiness and fatigue, and improvement in her fibromyalgia, while her postoperative sleep study showed an RDI of 11.

## Case 2

JR, a 23-year-old long haul truck driver, was found to have extremely severe obstructive sleep apnea with RDI of 102. He was intolerant of CPAP therapy due to claustrophobia and a sense of suffocation. Due to disease severity and inability to comply with standard treatment, his commercial driver's license was suspended, and he was placed on medical disability. His profile view and cephalometric x-ray showed retrognathia. He underwent maxillomandibular and staged genioglossus advancement with resolution of his daytime sleepiness and normalization of his sleep study with RDI of 9 (Figure 1 a and b).

## Case 3

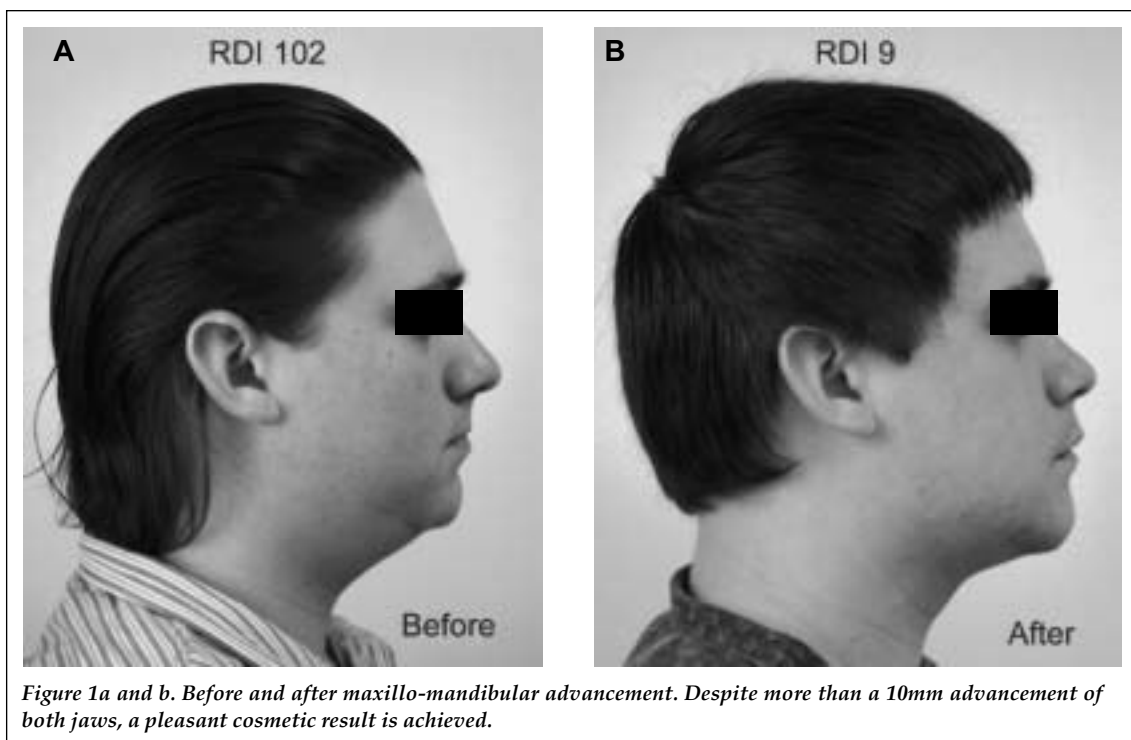
TW, a 43-year-old man, was diagnosed with severe obstructive sleep apnea with RDI 37 increasing to 46 events per hour during REM sleep. He was intolerant of CPAP due to barotrauma induced nasal congestion. His facial features showed retrognathia and class 2 malocclusion with "underbite" deformity. He underwent hyoid suspension and genioglossus advancement with resolution of symptoms of obstructive sleep apnea and an RDI of 3. Elimination of his daytime sleepiness was important so as to prevent a work place accident in that he was employed as a driver of a concrete truck.

## DISCUSSION

While CPAP therapy is commonly effective in treating sleep disordered breathing and the resultant daytime sleepiness, acceptance and compliance with treatment is often a problem. A University of Kentucky study showed that scant few patients really wear a CPAP device

# COVER STORY

COMPREHENSIVE RECONSTRUCTIVE SURGERY FOR OBSTRUCTIVE SLEEP APNEA



each night for the full duration of sleep, with only about half of the patients using CPAP for more than half the night, five or more nights per week.<sup>25</sup> Objective CPAP computer scorecard verification of nightly compliance has consistently revealed gross subjective overestimation of usage of the device by patients.<sup>26</sup> The minimally acceptable threshold for CPAP use, both amount of pressure and its duration of use from night to night, are not known.<sup>27</sup> Failure to comply with CPAP therapy has been reported to be between 25% to 50%.<sup>3,4,28</sup> Hence, there is a large and growing patient pool that needs an alternate treatment to CPAP but with comparable outcome measures. Comprehensive surgical therapy for OSA, consisting of both hard and soft tissue manipulations, can readily salvage patients who are otherwise unable, unwilling, or incapable of CPAP treatment. An overview of current surgical methods, rationale for application, and outcome information is presented below.

Surgical opinion is indicated when CPAP therapy: fails to reverse OSA symptoms or nor-

malize sleep indices; requires excessive CPAP airway pressures; is exceptionally inconvenient or physically intolerable; proves undesirable or impossible due to psychiatric reasons; or is refused by the patient. Personnel with OSA who operate airplanes,<sup>29</sup> trains, boats, heavy equipment, trucks, buses, ambulances, or otherwise engage the public in a critical capacity all need to be carefully scrutinized for the adequacy of compliance with CPAP and deserve consideration for surgical input early after diagnosis. Other occupations that impact public safety that should have early referral for surgical evaluation might include control tower administrators or those that bear firearms, for example, police, military, or governmental officials. When given a choice, many young to middle-aged patients prefer to have surgery in order to avoid the constraint of nightly use of CPAP for the rest of their lives. Obvious morphological abnormalities such as nasal obstruction, tonsillar hypertrophy, macroglossia, or retrognathia are corrected by surgery, potentially obviating the need for long-term CPAP usage.

An appropriate history and comprehensive head and neck examination are made for every patient with OSA. Every treatment plan is individualized taking into consideration: age, co-morbidities, expectations, body-mass index, PSG parameters of RDI, LSAT and EKG changes, facial profile, dentition, examination of the cervical viscera, and cephalometry. An evaluation of the airway is made with a flexible endoscope to rule out a pathological cause of the airway obstruction and in attempt to determine the one or more sites of dynamic airway collapse.

Reconstructive airway surgery for OSA requires expertise in manipulation of both soft and hard tissues of the upper aero-digestive tract so as to optimize outcomes. Nasal valve procedures, septoplasty, inferior turbinate reduction,<sup>30</sup> or adenoidectomy are common techniques to open the nasal airway. Tonsillectomy is beneficial to OSA treatment by expanding the caliber of the pharyngeal airway, especially when the finding of tonsillar hypertrophy is present.<sup>31</sup> Uvulo-palato-pharyngoplasty (UPPP)<sup>32</sup> is useful for focal airway occlusion posterior to the palate. Skeletal protrusion by way of genio-glossus advancement (GGA)<sup>33</sup> or related procedures,<sup>34,35</sup> hyoid suspension (HS),<sup>36</sup> or maxillo-mandibular advancement (MMA)<sup>37</sup> is typically performed for airway narrowing at the tongue base. In select circumstances, expansion of a narrow hard palate will be beneficial by improving both the oral and nasal airways.<sup>38</sup> Tracheotomy is usually reserved for those with obesity-hypo-ventilation syndrome with carbon dioxide retention,<sup>39,40</sup> over-lap syndrome, or impending cardiopulmonary failure when CPAP has proven ineffective. Radio-frequency tissue ablation, such as the Somnus device, may have a role in treatment of the palate or tongue base,<sup>41</sup> but at present is strictly used for salvage therapy by this author until shown to be a practical and efficacious technique. Other surgical procedures that are currently used for OSA treatment include laser assisted uvulo-palatoplasty (LAUP)<sup>42</sup> and the Repose bone screw anchor system.<sup>43</sup> Both of

these techniques have shown only modest impact as a treatment for OSA.

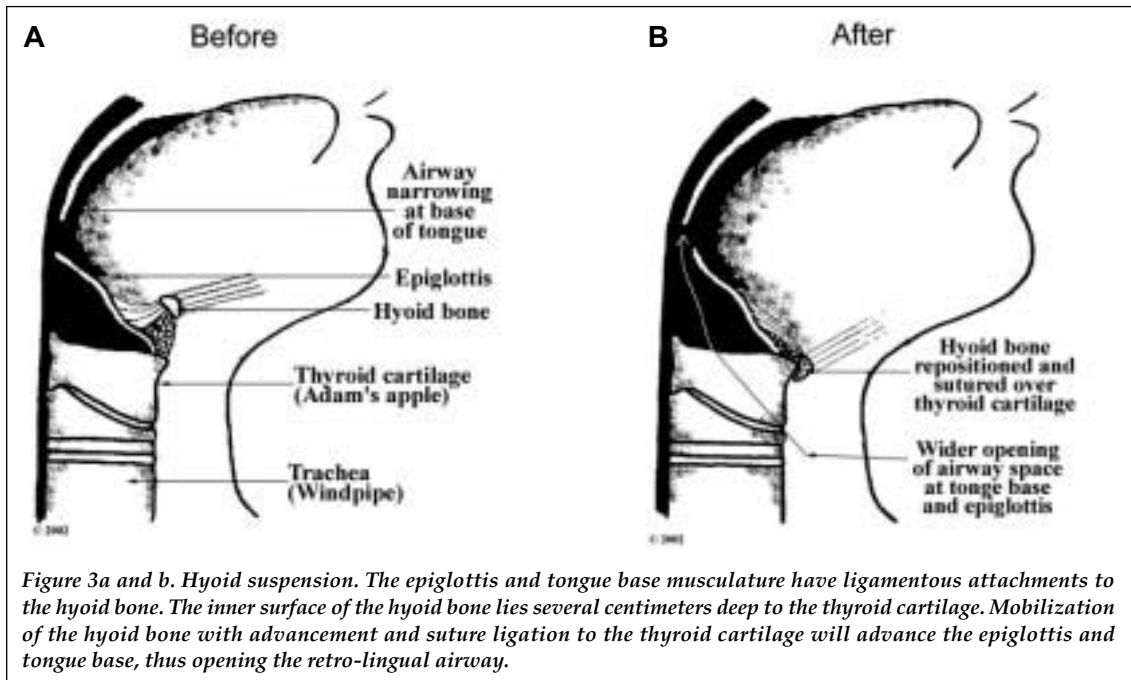
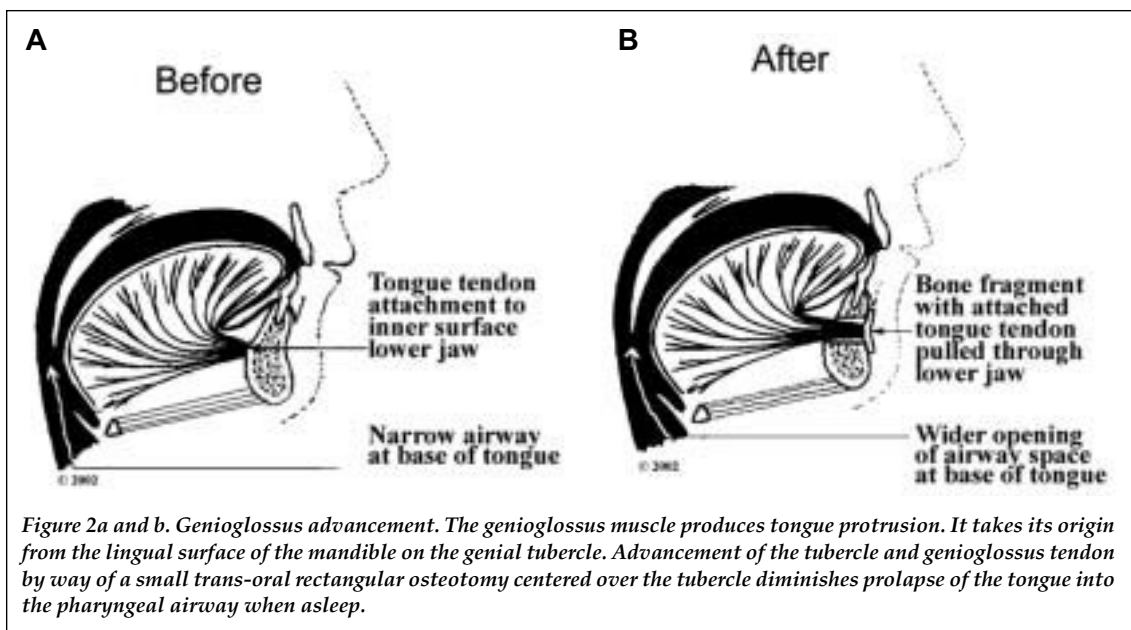
Procedures that protrude the facial skeleton are now an integral part of OSA surgical therapy. The goal of these procedures is to relieve site-specific airway occlusion predominantly at the base of the tongue. The GGA<sup>44</sup> is effective by placing tension on the genioglossus muscle and tendon. A trans-oral 9×18 mm osteotomy, centered on the chin and genial tubercle, is made below the tooth roots, sparing the inferior border of the jaw. The lingual surface of the bone fragment with the attached tendon is advanced over the facial surface of the mandible preventing retro-lingual airway occlusion (Figures 2a and b). The HS produces an advancement of the tongue base by mobilization, advancement, and ligation of the hyoid bone to the superior surface of the thyroid cartilage through external incision on the neck, again producing relief of obstruction at the tongue base (Figures 3a and b). Combined retro-palatal and retro-lingual airway expansion can be seen after at least 1 cm of advancement by Lefort 1 osteotomy of the maxilla and sagittal split osteotomy of the mandibular rami. Both osteotomy sites are secured with rigid fixation and augmented with cranial bone grafts so as to minimize the potential for relapse<sup>45</sup> (Figures 4a and b).

Most patients begin a course of surgical treatment for OSA by targeted multi-level intervention of the nose, oropharynx and/or hypopharynx. A typical surgery might consist of turbinate reduction, palatoplasty, and genioglossus advancement followed by 3-month post-operative sleep study. In another situation, with clear retro-lingual collapse, initial treatment might consist of hyoid suspension and genioglossus advancement. If mandibular retrognathia is present, MMA is a better option. MMA is more commonly reserved for those patients who have undergone one or more of the above mentioned procedures, but still have persistent disease.

The outcome of OSA surgery is comparable to CPAP treatment as measured in the sleep

# COVER STORY

COMPREHENSIVE RECONSTRUCTIVE SURGERY FOR OBSTRUCTIVE SLEEP APNEA



lab. Since the RDI and LSAT are gross measures of OSA disease intensity, representing the frequency of respiratory obstruction and nadir of oxygen saturation, they are commonly used to compare treatment outcomes. The criteria

used to define a "cure" by the Stanford sleep community are: relief of subjective excessive daytime sleepiness; normalization of sleep architecture; post-surgical RDI and LSAT equal to CPAP results, or if no CPAP result was avail-

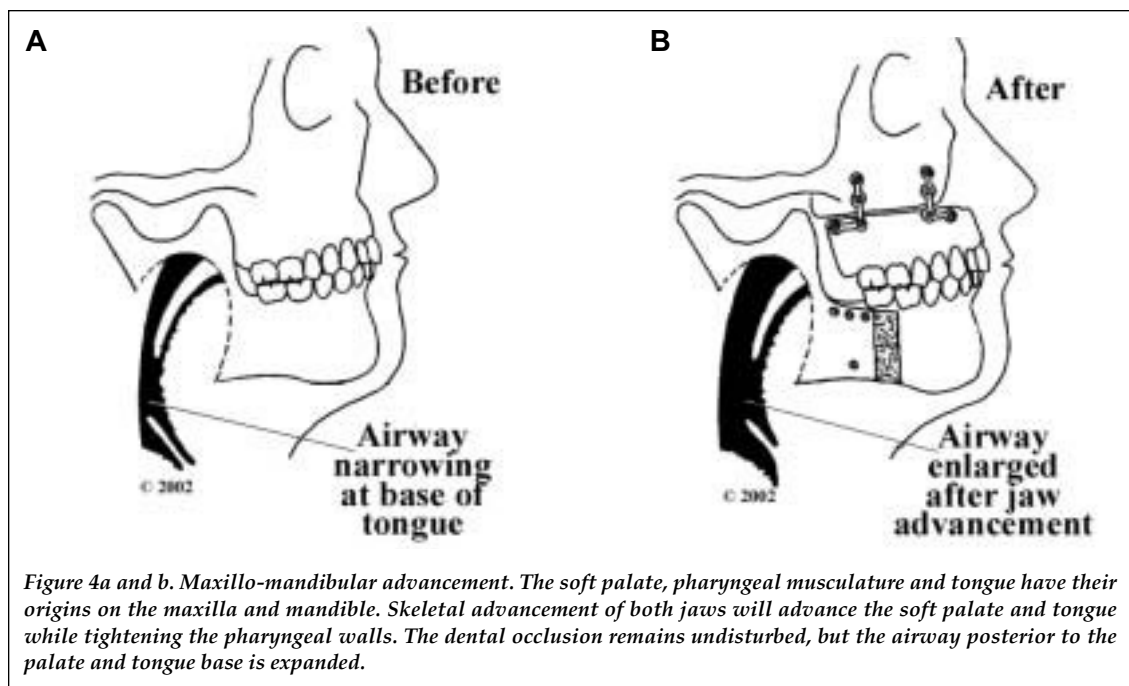


Figure 4a and b. Maxillo-mandibular advancement. The soft palate, pharyngeal musculature and tongue have their origins on the maxilla and mandible. Skeletal advancement of both jaws will advance the soft palate and tongue while tightening the pharyngeal walls. The dental occlusion remains undisturbed, but the airway posterior to the palate and tongue base is expanded.

able, then  $RDI > 50\%$  reduction and  $RDI < 20$ . The surgical outcomes of more than 400 patients treated by a surgical protocol have been reported.<sup>46,47</sup> Phase I therapy consisted of combinations of nasal reconstructive surgery, septoplasty, turbinate reduction, uvulo-palato-pharyngoplasty, tonsillectomy, genioglossus advancement, or hyoid suspension. Phase 2 therapy consisted of maxillo-mandibular advancement and was reserved for patients that were unsuccessfully treated in the first stage of therapy or who had retrognathia. For those patients who followed through the protocol there was a 97% chance of surgical success, as defined by the aforementioned definitions.

The results of phase I surgery showed that surgical success was greatest with mild OSA and least with severe OSA. Mild disease ( $RDI < 20$ ,  $LSAT > 85\%$ ) enjoyed a 77% chance of surgical success with phase I procedures and often avoided MMA. In contrast, severe OSA ( $RDI > 60$ ,  $LSAT < 70$ ) experienced only a 42% likelihood of success with phase I procedures alone and often needed MMA. The preoperative average RDI of those successfully treated

was 48, which decreased to 9 after surgery and was statistically equivalent at 7 while on CPAP. The preoperative LSAT was 75 and increased to 86 after surgery and while on CPAP. These findings have been independently confirmed by other investigators showing success rates from 78%,<sup>48</sup> 45%,<sup>49</sup> to 42%<sup>50</sup> for phase 1 procedures.

Those patients that were not successful in the phase I portion of the protocol were offered the phase II maxillo-mandibular advancement. These patients enjoyed a 97% chance of surgical success despite the fact that most of these patients had severe disease. The preoperative RDI was 72 and decreased to 7 after surgery compared with 8 on CPAP. Likewise, the LSAT before phase II surgery was 64 and increased to 87 after surgery and while on CPAP. It appears that surgery or CPAP therapy can control OSA-induced respiratory events and fall in oxygen levels equally well.

A select group of patients may require only one operation in order to be free of their OSA. Those patients with a small jaw, receding chin and "underbite" (retrognathia) might be expected to have a very high likelihood of surgical

success by correction of the skeletal deficiency. When chosen to meet specific criteria for height/weight ratios and measured retrognathia of the mandible, Hochban found 95% (36 out of 38 patients) were cured of their apnea by upper and lower jaw advancement.<sup>51</sup> This approach has been confirmed in a recent study. Fifty consecutive patients who underwent MMA, and other select procedures as the initial operation, enjoyed a success rate of 100%.<sup>52</sup>

The comprehensive surgical treatment of OSA produces successful results that are durable over several years' time. At a mean of 39 months after palatoplasty, hyoid suspension and genioglossus advancement,<sup>53</sup> 83% (30 out of 36 patients) showed sustained resolution of OSA. Those that failed were statistically more likely to have gained weight. Powell and Riley demonstrated that 90% (36/40 patients) have shown "successful long-term clinical outcome."<sup>54</sup> The average follow-up was 51 months with a preoperative RDI of 71.2 and long-term RDI of 7.6 and CPAP RDI of 7.6. This was independently confirmed by a German group who performed MMA on jaw-deficient patients with follow-up a minimum of 2 years.<sup>55</sup> Fifteen patients demonstrated a preoperative RDI of 51 and long-term RDI of 8.5. The long-term stability of the jaw position has also been confirmed in a radiological study.<sup>56</sup>

Surgery or CPAP therapy can treat OSA equally well. When a comprehensive surgical armamentarium is used to treat OSA the result is predictable, portable, and well tolerated. Surgery for OSA can be used to rescue patients who are unable to use CPAP and to diminish the profound long-term medical risks incurred by untreated OSA. Once surgical success has been achieved, appropriate attention to weight stabilization or weight loss and other lifestyle issues becomes a lifelong commitment to remain "cured" of OSA.

The option of comprehensive upper airway reconstructive surgery for OSA should be presented to patients as part of their initial treatment planning so that they know all treatment options. In that CPAP therapy is discarded by many patients, reconstructive

airway surgery for OSA is a fine treatment alternative, but must include maxillo-facial techniques to achieve consistent success.

### Table of Abbreviations

CPAP	continuous positive airway pressure
GGA	genioglossus advancement
HS	infra-hyoid myotomy and hyoid suspension
LSAT	lowest oxygen saturation
MMA	maxillo-mandibular advancement
OSA	obstructive sleep apnea
PSG	polysomnogram, sleep study
RDI	respiratory disturbance index, apnea-hypopnea index
UPPP	uvulo-palato-pharyngoplasty

### REFERENCES

1. Badr M. Pathogenesis of obstructive sleep apnea. *Prog Cardiovasc Dis.* 1999;41:323-330.
2. Sullivan CEM, Berthon-Jones FGI, Eves L. Reversal of obstructive sleep apnea by continuous positive airway pressure applied through the nose. *Lancet.* 1:862-865.
3. Nino-murcia G, McCann C, Bliwise D, Guilleminault C, Dement W. Compliance and side effects in sleep apnea patients treated with nasal continuous positive airway pressure. *West J Med.* 1989;150:165-169.
4. Krieger J. Long-term compliance with nasal continuous positive airway pressure (CPAP) in obstructive sleep apnea patients and nonapneic snorers. *Sleep.* 1992; 15:s42-s45.
5. Rolfe I, Olson L, Saunders N. Long-term acceptance of continuous positive airway pressure in obstructive sleep apnea. *Am Rev Respir Dis.* 1991;144:1130-1133.
6. Schmidt-Nowara W, Lowe A, Wiegand L, Cartwright R, Perez-Guerra F, Menn S. Oral appliances for the treatment of snoring and obstructive sleep apnea: a review. *Sleep.* 1995;18:501-510.
7. Henderson J, Strollo P. Medical management of obstructive sleep apnea. *Prog Cardiovasc Dis.* 1999;41:377-386.
8. Kashyap R, Hock L, Bowman T. Higher prevalence of smoking in patients diagnosed as having obstructive sleep apnea. *Sleep and Breathing.* 2001;5:167-172.
9. Senior B, Khan M, Schimmer C, Rosethal L, Benniger M. Gastroesophageal reflux and obstructive sleep apnea. *Laryngoscope.* 2001;111:2144-2146.
10. Sukanuma N, Shigedo Y, Adachi H, et al. Association of gastroesophageal reflux disease with weight gain and apnea, and their disturbance on sleep. *Psychiatry Clin Neurosci.* 2001;55:255-256.
11. Sin D, Mayers I, Man G, Pawluk L. Long-term compliance rates to continuous positive airway pressure in obstructive sleep apnea. *Chest.* 2002;121:430-435.
12. Redline S, Strohl K. Recognition and consequences of obstructive sleep apnea hypopnea syndrome. *Otolaryngol Clin North Am.* 1999;32:303-331.

13. Richert A, Ansarin K, Baran A. Sleep apnea and hypertension: pathophysiological mechanisms. *Semin Nephrol.* 2002;22:71-77.
14. Lanfranchi P, Somers V. Obstructive sleep apnea and vascular disease. *Respir Res.* 2001;2:315-319.
15. Peppard P, Young T, Palta M, Skatrud J. Prospective study of the association between sleep-disordered breathing and hypertension. *New Engl J Med.* 2000;342:1378-1384.
16. Schafer H, Koehler U, Weig S, Hasper E, Tasci S, Luderitz B. Obstructive sleep apnea as a risk marker in coronary artery disease. *Cardiology.* 1999;92:79-84.
17. Andreas S, Schulz R, Werner G, Kreuzer H. Prevalence of obstructive sleep apnoea in patients with coronary artery disease. *Coron Artery Dis.* 1996;7:541-545.
18. Wessendorf T, Teschler H, Wang Y, Konietzko N, Thilman A. Sleep-disordered breathing among patients with first-ever stroke. *J Neurol* 2000;247:41-47.
19. Bassetti N, Aldrich M. Sleep apnea in acute cerebrovascular diseases: final report on 128 patients. *Sleep.* 1999;22:217-223.
20. Day R, Gerhardstein R, Lumley A, Roth T, Ruesenthal L. The behavioral morbidity of obstructive sleep apnea. *Prog Cardiovasc Dis.* 1999;41:341-354.
21. Kribbs N, Pack A, Kline L, et al. Effects of one night without nasal CPAP treatment on sleep and sleepiness in patients with obstructive sleep apnea. *Am Rev Respir Dis.* 1993;147:1162-1168.
22. Poceta S, Loube D, Kellgren E, Bizik K, Mitler M. Mortality in obstructive sleep apnea; association with impaired wakefulness. *Sleep Breath.* 1999;3:3-8.
23. Leeuw P. On sleep and death: cardiovascular risk of the obstructive sleep apnea syndrome. *Neth J Med,* 1999; 54:188-190.
24. Powell N, Schechtman K, Riley R, Li K, Troell R, Guilleminault C. The road to danger: the comparative risks of driving while sleepy. *Laryngoscope.* 2001; 111:887-893.
25. Anstead M, Phillips B, Buch K. Tolerance and intolerance to continuous positive airway pressure. *Curr Opin Pulm Med.* 1998; 4:351-354.
26. Rauscher H, Formanek D, Popp W, et al. Self reported vs measured compliance with nasal CPAP for obstructive sleep apnea. *Chest* 1993;6:1675-1680
27. Stepnowsky C, Moore P. Nasal CPAP treatment for obstructive sleep apnea: developing a new perspective on dosing strategies and compliance. *J Psychosom Res.* 2003; 54:599-605.
28. Kribbs NB, Pack AI, Kline LR. Objective measurement patterns of nasal CPAP use by patients with obstructive sleep apnea. *Amer Rev Resp Dis.* 1993;147:887-895.
29. Pantou S, Norup P, Videbaek R. Case report: obstructive sleep apnea—an air safety risk. *Aviat Space Environ Med.* 1997;68:1139-1143.
30. Verse T, Maurer J, Pirsig W. Effect of nasal surgery on sleep-related breathing disorders. *Laryngoscope.* 2002;112:64-68.
31. Verse T, Kroker B, Pirsig W, Brosch S. Tonsillectomy as a treatment of obstructive sleep apnea in adults with tonsillar hypertrophy. *Laryngoscope.* 2000;110:1556-1559.
32. Senior B, Rosenthal L, Lumley A, Gerhardstein R, Day R. Efficacy of uvulopalatopharyngoplasty in unselected patients with mild obstructive sleep apnea. *Otolaryngol Head Neck Surg.* 2000;123:179-182.
33. Silverstein K, Costello B, Giannakopoulos H, Hendler B. Genioglossus muscle attachments: an anatomic analysis and the implications for genioglossus advancement. *Oral Surg Oral Med Oral Pathol Oral Radiol Endod.* 2000;90:686-688.
34. Krekmanov L, Andersson L, Ringqvist M, et al. Anterior-inferior mandibular osteotomy in treatment of obstructive sleep apnea syndrome. *Int J Adult Orthod Orthognath Surg.* 1998;13:289-298.
35. Hendler B, Costell B, Silverstein K, Yen D, Goldberg A. A protocol for uvulopalatopharyngoplasty, mortised genioplasty, and maxillomandibular advancement in patients with obstructive sleep apnea: an analysis of 40 cases. *J Oral Maxillofac Surg.* 2001;59:892-897.
36. Riley R, Powell N, Guilleminault C. Obstructive sleep apnea and the hyoid: a revised surgical procedure. *Otolaryngol Head Neck Surg.* 1994;111:717-721.
37. Powell N, Guilleminault C, Riley R. Mandibular advancement and obstructive sleep apnea syndrome. *Eur Physiopathol Respir.* 1983;19:607.
38. Cistulli P, Palmisano R, Poole M. Treatment of obstructive sleep apnea syndrome by rapid maxillary expansion. *Sleep.* 1998;21:831-835.
39. Li K, Powell N, Riley R, Zonato A, Gervacio L, Guilleminault C. Morbidly obese patients with severe obstructive sleep apnea: is airway reconstructive surgery a viable treatment option? *Laryngol.* 2000; 110:982-987.
40. Berger K, Ayappa I, et al. Obesity hypoventilation syndrome as a spectrum of respiratory disturbances during sleep. *Chest.* 2001;120:1231-1236.
41. Stuck B, Maurer J, Hormann K. Tongue base reduction with radiofrequency tissue ablation: preliminary results after two treatment sessions. *Sleep Breath.* 2000;4:155-162.
42. Finkelstein Y, Stein G, Ophir D, Berger R, Berger G. Laser-assisted uvulopalatoplasty for the management of obstructive sleep apnea: myths and facts. *Arch Otolaryngol Head Neck Surg.* 2002;128:429-434
43. Miller FR, Watson D, Malis D. Role of the tongue base suspension suture with The repose system bone screw in the multilevel surgical management of obstructive sleep apnea. *Otolaryngol Head Neck Surg.* 2002 Apr;126(4):392-398.
44. Li K, Riley R, Powell N, Troell R. Obstructive sleep apnea surgery: genioglossus advancement revisited. *J Oral Maxillofac Surg.* 2001;59:1181-1184.
45. Waite P, Tejera T, Anucul B. The stability of maxillary advancement using Lefort I osteotomy with and without genial bone grafting. *Int J Oral Maxillofac Surg.* 1996;25:264-267.
46. Li K, Powell N, Riley R, Troell R, Guilleminault C. Overview of phase I surgery for obstructive sleep apnea syndrome. *Ear Nose Throat J.* 1999;78:836-845.
47. Li K, Riley R, Powell N, Troell R, Guilleminault C. Overview of Phase II Surgery for Obstructive Sleep Apnea Syndrome. *Ear Nose Throat J.* 1999;78:851-857.
48. Johnson N, Chinn J. Uvulopalatopharyngoplasty and inferior sagittal mandibular osteotomy with genioglossus advancement for treatment of obstructive sleep apnea. *Chest.* 1994;105:278-283.

49. Hendler B, Costello B, Silverstein K, Yen D, Goldberg A. A protocol for uvulopalatopharyngoplasty, mortised genioplasty, and maxillomandibular advancement in patients with obstructive sleep apnea: an analysis of 40 cases. *J Oral Maxillofac Surg*. 2001;59:892-897.
50. Ramirez S, Loube D. Inferior sagittal osteotomy with hyoid bone suspension for obese patients with sleep apnea. *Arch Otolaryngol Head Neck Surg*. 1996;122:953-957.
51. Hochban W, Conradt R, Brandenburg U, Heitmann J, Peter J. Surgical Maxillofacial Treatment of Obstructive Sleep Apnea. *Plas Reconstr Surg*. 1997;99:619-626.
52. Prinsell J. Maxillomandibular advancement surgery in a site-specific treatment approach for obstructive sleep apnea in 50 consecutive patients. *Chest* 1999;116:1519-1529.
53. Neruntarat C. Genioglossus advancement and hyoid myotomy: short-term and long-term results. *J Laryngol Otol*. 2003;260:286-290.
54. Riley R, Powell N, Li K, Troell R, Guilleminault C. Surgery and obstructive sleep apnea: long-term clinical outcomes. *Otolaryngol Head Neck Surg*. 2000;122:415-431.
55. Conradt R, Hochban W, Brandenburg U, Heitmann J, Peter J. Long-term follow-up after surgical treatment of obstructive sleep apnoea by maxillomandibular advancement. *Eur Respir J*. 1997;10:123-128.
56. Nimkarn Y, Miles P, Waite P. Maxillomandibular advancement surgery in obstructive sleep apnea syndrome patients: long-term surgical stability. *J Oral Maxillofac Surg*. 1995;53:1414-1418.